

50X1-HUM

**Page Denied**

Next 2 Page(s) In Document Denied

FROM THE SANATORIUM FOR TUBERCULOSIS IN THE BONES AND JOINTS,  
KAKASSZEK AND THE CENTRAL RESEARCH INSTITUTE OF THE BLOOD  
TRANSFUSION SERVICE, BUDAPEST, HUNGARY

e

## ARTHROPLASTY USING OF BIOPLAST IN TUBERCULOUS COXITIS


By

PÁL KOVÁCS, M.D. and MIHÁLY GERENDÁS, Ph.D.

In the therapy of articular tuberculosis the aim has for a long time been to preserve the mobility of joints, but up to recent times there has not been much chance of success. The advent of antituberculotics raised great hopes also in this sphere and, in fact, the number of spontaneously healed mobile joints has increased, particularly in cases where treatment was started early enough. Unfortunately, arthroplasty with the application of metal or synthetic interpositums to promote mobility did not yield good results and in the literature opinion became general that the use of vitallium or acrylate caps in tuberculosis of the joints was contraindicated.

The absorbable cap produced from fibrin powder by high pressure represents a significant advance (Fig. 1). This synthetic material of protein named bioplast shows affinity with the tissues, contains no toxic or carcinogenic substances, and possesses the required consistency and elasticity; more important than any other quality, however, is its susceptibility to being broken down by proteolytic enzymes and absorbed. By the aid of chemical pre-treatment, absorption time can be regulated to take from three or four weeks to seven to eight months, as required.

The first models were given a trial in the hip joints of dogs by Zinner, Gerendás, and Biró (11), and then, on the basis of the results, in clinical practice. A fibrin cap—fashioned to fit the joint in shape and size—placed on the femoral head prevents merging ossification of contiguous articular endings. After operation the cap promotes mobility of the limb and under its protection cartilage develops on the articular surfaces owing to the influence of function. Finally, six to eight months



*Fig. 1.*  
Bioplast cap.

following implantation—when regeneration has run its course—the cap is absorbed and disappears without leaving behind any trace. This circumstance ensures in the most favourable manner free motion of the joint (2, 3).

Therapy of tuberculous coxitis aimed at restoring motion calls for consideration of three aspects:

Whether maintenance of, or insistence on, motion involves no danger of relapse.

Differentiation of cases where mobility is desirable from those where stable, stiff joints offer an advantage.

The most suitable procedure for obtaining good motion in articular tuberculosis.

1) Prior to the introduction of antituberculotics the view was as good as unanimous that a tuberculous process can be healed only by complete ossification; therefore the objective was to stiffen the joint at any price. However, observations recorded during the ten years that have elapsed since initiation of the use of antituberculotics have drawn attention to many angles that might lead to more complete healing of tuberculosis in the joints (1, 4, 6, 10).

For several years full recovery and satisfactory motion have been noted in the treatment of early, superficial, or synovial processes. In most instances, well-functioning joints have been obtained after elimination of foci and necrectomy. Resection in coxotuberculosis has also been followed by uneventful recovery, as well as restoration of good motion within a few months, and the favourable results persist after the passage of several years. Hence in these cases the maintenance of motion has exerted no harmful effects on the course of tuberculosis. Still more encouraging is the fact that the dreaded dangers of former

times, miliary and meningeal dissemination, have not been encountered among our more than 3000 cases of osteotuberculosis treated in the last ten years. It is therefore plausible that we are in favour of restoring motion (7).

2) In our experience, endeavours to retain motion are worthwhile in every case where the slightness of articular destruction permits hope of success. If after a time it becomes obvious that the joint shows functional insufficiency associated with pain and inadequate capacity, only then is the stabilizing operation performed. To further our efforts we omit—if possible—the application of plaster and employ intensive water cure and physiotherapy when tuberculosis has assumed quiescence.

3) The literature agrees on the point that arthroplasty with vitalium and other prostheses does not produce favourable results and is thus contraindicated in general (5, 8). However, as evidenced by our experiences, fibrin caps, too, ensure the maintenance of motion, while owing to absorption, their use is free from the serious disadvantages of prostheses; moreover, they contribute to the development of smooth articular surfaces and are well tolerated by tuberculous tissue.

In 1955 these considerations induced us to begin the use of fibrin caps in hip resections. So far we have performed twenty operations. The present paper gives a report on ten cases where the follow-up period since surgery has been two to three years. The results of later operations are not evaluated here, but we may remark that they are equally encouraging.

#### METHOD

Our operated cases include five male and five female patients (Table I).

*Pretreatment* usually takes one to three months. Rest is ensured by extension, in the presence of severe pain, by plaster. As medicamentous therapy Streptomycin (SM) + isonicotinic acid hydrazide (INH), or INH + para-aminosalicylic acid (PAS) are administered in combination. The object of pretreatment is to obtain regression. If destruction increases and the joint is threatened by the danger of more extensive destruction, the patient is operated on without delay.

*Indication.*—Stiffness and limited mobility of the contralateral side constitute absolute indications for surgery. Apart from these symptoms, slight destruction in the case of children, young women, and persons with a sedentary occupation is also regarded as an indication for surgery. Patients having to perform difficult movements in an up-

TABLE I

No.	Name	Age	Sex	Onset of disease in years	Diagnosis	Histology
1.	B.J.	8 years	boy	½	Tuberculous coxitis, right side	Tuberculosis
2.	K.M.	14 years	girl	4	Tuberculous coxitis, right side	Regressive tuberculosis
3.	B.T.	19 years	girl	2	Tuberculous coxitis, left side	Caseous tuberculosis
4.	Sz.Zs.	23 years	girl	6	Tuberculous coxitis? left side	Chronic inflammation
5.	B.J.	12 years	boy	1	Tuberculous coxitis, right side	Regressive tuberculosis
6.	B.L.	16 years	boy	1	Tuberculous coxitis, right side	Regressive tuberculosis
7.	M.M.	8 years	boy	5	Tuberculous coxitis, right side, tuberculous spondylitis, in dorsal vertebrae 8, 9, 10, 11	Regressive tuberculosis
8.	Sz.Gy.	15 years	boy	½	Tuberculous coxitis, right side Dislocation of coxa, left side	Caseous tuberculosis
9.	F.M.	9 years	girl	½	Tuberculous coxitis, left side	Tuberculosis
10.	H.E.	32 years	woman	¼	Tuberculous coxitis, right side	Granulation, tuberculosis?

right position fare better with stable, stiff joints. However, final decision usually depends on surgical findings; in most cases of hip resection we therefore make preparations also for the use of arthroplasty with a fibrin cap.

*Surgical Technique.*—Exposure is performed by Smith-Peterson's incision (9). The diseased articular parts are removed by resection and the surfaces are shaped as in preparation for plastic surgery with vitalium. Any defects of the head or the articular acetabulum are filled with "blood cake", chips taken from the hip bone, SM and penicillin powder. The "blood cake" is made by mixing of blood from the cavity and fibrin-thrombin powder. After filling of the defects, the cap is pulled on the femoral head. If the chief site of infection is in the articular acetabulum, a cap of adequate size is placed in the latter and the head set. In the case of active, suppurative processes, through drainage is applied and after operation plaster is put on the pelvis for a period of two or three weeks. Irrigation with a solution of SM + INH + penicillin is effected daily until the development of secretion has ceased completely, which generally ensues in four to ten days. In regressive, cicatrizing processes, drainage and plaster are omitted; preference is given to extension traction.

*After-Treatment.* Mobilization of the affected limb requires the most careful individual consideration. Initiation of active and passive movement in bed should rely strictly on clinical, laboratory, and X-ray findings. As a rule, perfect rest is observed for two to four weeks, then physiotherapy is gradually introduced, followed by baths and subaqueous exercise. Usually, the patient begins to move about with crutches after two or three months, while treatment is continued. The time for starting unaided movement is determined by the patient's condition and capacity. Antituberculous are administered during the whole time of therapy (Table II).

#### CASES

Ten patients have been followed up for two or three years (Table III)<sup>1</sup>. The most encouraging results are demonstrated by the fact that the tuberculous process has healed in all of these ten cases, articular capacity is good, the patients use no aid and walk without pain.

Perfect motion has been obtained in three cases; in one case motion

---

<sup>1</sup> Our cases are under control at present since five years. They are showing further improvement. Our new cases are also successful.

TABLE II


No.	Pretreatment			Operation	After-Treatment			
	Time months	Stabilization	Drug employed	Date	Extension Plaster Bed rest months	Initiation of physiotherapy bathing months	Start in using bathing months	Start of unaided walking months
1.	2	plaster	SM, INH	Sept. 15, 1955	1	1	4	6
2.	3	extension	SM, INH	Oct. 25, 1955	1	1	2	3
3.	2	extension	SM, INH	Oct. 20, 1955	1+1	1	8	11
4.	2	plaster	SM, INH	Oct. 25, 1955	1	1	6	8
5.	9	extension	SM, INH, PAS	Nov. 29, 1955	1	1	2	4
6.	4	extension	SM, INH, PAS	Jan. 10, 1956	1	1	2	3
7.	6	plaster	SM, INH, PAS	Jan. 12, 1956 July 8, 1955 Spondylodesis	1	1	1½	4
8.	2	extension	SM, INH, PAS	Febr. 2, 1956	1	1	2	24
9.	6	extension	SM, INH, PAS	Jan. 24, 1957	5	5	6	8
10.	2	extension	SM, INH	April 2, 1957	1	1	2	12

ARTHRORPLASTY IN TUBERCULOUS COXITIS

TABLE III

No.	Motion per cent			Tuberculosis	Pain upon motion	Load-bearing capacity	Time of results months	Follow-up period years	
	Before operation	After operation							
		flexion	abduction						adduction
1.	painful contractura	100	100	100	healed	absent	excellent	6	3 1/2
2.	absent	30	20	20	healed	absent	excellent	8	3 1/2
3.	painful contractura	90	100	100	healed	slight	good	24	3 1/2
4.	absent	bone ankylosis			healed	absent	excellent	8	3 1/2
5.	absent	50	20	20	healed	absent	excellent	6	3 1/2
6.	absent	80	100	100	healed	absent	excellent	12	3 1/4
7.	absent	40	20	20	healed	absent	good	6	3
8.	painful contractura	50	50	50	healed	absent	improving	24	3
9.	absent	50	10	10	healed	absent	excellent	9	2
10.	painful contractura	90	100	100	healed	slight	good	18	2





*Fig. 2-A.*

*Fig. 2-B.*

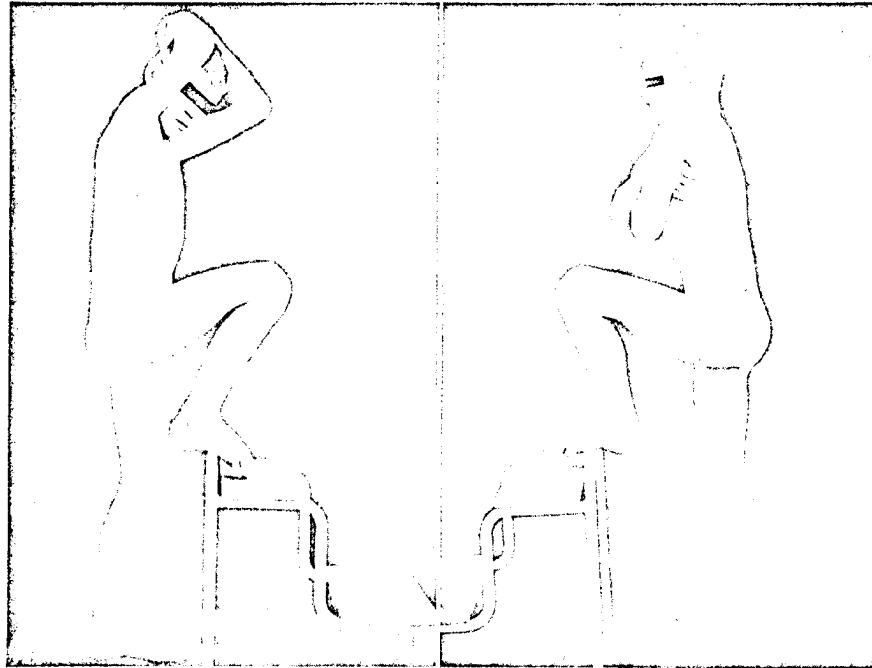
*Fig. 2-A.* Radiograph prior to operation. Presence of sequestrum in the acetabulum is clearly visible at Y cartilage.

*Fig. 2-B.* Radiograph after one year following operation. The acetabular focus has been completely filled.

is good, in five satisfactory but not quite complete. In one operated patient subluxation was followed by ankylosis. Since entire freedom from symptoms persists, no fresh operation has been undertaken.

For the purpose of illustration, three case records are presented in detail.

*Case No. 1.* J.B., a boy aged 8 years, was admitted on July 13, 1955, with complaints of six months' standing in the right hip joint. At admission a 150° flexion-adduction contracture was found, causing intense pain on every attempt at motion, particularly upon abduction, adduction, and extension. The periarthric region was swollen. A plaster bandage was put on the pelvis and a course of SM+INH treatment started. The general condition improved, but as radiology revealed increased destruction of the acetabulum (Fig. 2-A), surgery was undertaken on Sept. 15, 1955. The articular soft parts were found to be caseous, the acetabulum cartilage was completely destroyed and at the Y chondrus there was an approximately nut-sized bone destruction spreading towards the pelvis. The femoral head appeared to be intact. After complete cleaning of the acetabulum, the surface was reformed and the acetabular defect sealed with a fibrin cap. Postoperative treatment consisted of extension and the administration of SM+INH. After a month the process was compensated, thus active and passive physiotherapy was begun in bed and completed by subaqueous exercises. In the fourth month the patient could use crutches, was free from complaints, and in the sixth month was able to walk unaided. Since his discharge on May 21, 1956, we have seen the patient every three months, last time on January 18, 1959. As shown by radiology, the bone defect has been fully replaced in one year. Motion is completely free and painless; capacity is good (Figs. 2-C and D).



*Fig. 2-C.*

*Fig. 2-D.*


*Fig. 2-C.* Perfect motion of the right hip restored in six months.

*Fig. 2-D.* Statically complete function in the right hip.

*Case No. 2.* L.B., a boy aged 16 years, was admitted on October 20, 1955, with complaints of 12 months' standing. He had been given INH+PAS, his abscess had been tapped several times and he wore a walking machine. At admission the joint was fixed, a few degrees' motion occasioned severe pain, and at the side over an area as large as a palm some fluctuation could be suspected. Operation was performed on January 10, 1956. Preoperative radiology (Fig. 3-A) had disclosed an uneven, constricted articular orifice and small foci in the acetabulum as well as in the femoral head, with sclerotic environment. Surgical findings accordingly showed cicatrized granulation and destroyed cartilage. An abscess filled with turbid exudate was found between the buttocks. Histological investigation confirmed the presence of regressive tuberculosis. After operation (arthroplasty with fibrin cap) a plaster bandage was left on for two weeks; extension and SM+INH were employed concurrently. In a month the patient's condition had greatly improved. Active, passive, and subaqueous exercises were carried on and some walking with crutches allowed. When discharged on April 16, 1956, he could walk without crutches, without any pain; flexion was 60°. Since then he has been seen every three months, the last time on January 18, 1959. A year after being discharged, the patient had no complaints whatever, flexion amounted to 90°, and radiology showed the formation of cartilage in the joint (Fig. 3-B). Support was found to be excellent (Figs. 3-C and D).

ARTHROPLASTY IN TUBERCULOUS COXITIS

303



*Fig. 3-A.*

*Fig. 3-B.*

*Fig. 3-A.* Preoperative radiograph of right hip. The joint is uneven, constricted, destroyed, but signs of sclerosing are visible.

*Fig. 3-B.* Radiograph six months after operation. Articular cartilage surface is developing.




*Fig. 3-C.*

*Fig. 3-D.*


*Fig. 3-C.* Painless 60° flexion one year after operation.

*Fig. 3-D.* Statically excellent function in right hip.



*Fig. 4-A.*


Preoperative radiograph of pelvis. In the left hip congenital dislocation of the coxa. Complete absence of support. On the right, the iliac focus visible over the outer part of the acetabulum, has invaded the latter.




*Fig. 4-B.*

Reverse radiograph of right hip. The process threatened to destroy the whole coxa, therefore surgery was undertaken immediately.


*Case No. 3.* Gy.Sz., a boy aged 15 years, was admitted on November 16, 1955, with complaints of six months' standing in the right hip. Congenital dislocation of the left coxa was associated with a 12 cm. shortening and the absence of static function (Fig. 4-A). An abscess had developed on the right side. As pre-treatment we employed SM+INH, INH+PAS, extension, then incision and topical treatment of fistula and abscess, with SM+INH solution. Since in reverse radiology the coxa showed increased destruction of the acetabulum and the femoral head was suspected of sequestration, we decided on surgery. The operation was performed February 2, 1956. Right side hip joint resection was performed along with iliac neurectomy, arthroplasty with bioplast, and excision of the fistula. As verified by surgical findings, a green-nut-sized acetabular focus had spread and invaded laterally the joint. The synovia and the cavity displayed tuberculous destruction. The greater part of the femoral head was affected together with the cartilage, there was atrophy but no sign of sequestration. The diseased parts were removed and the articular surfaces re-formed. When the resulting defects had been filled with a mixture of SM + penicillin and clotted blood, the fibrin cap was fitted on the femoral head. Then, by a separate incision, the fistula and the abscess were excised to the line of healthy tissue. Histological investigation confirmed caseous tuberculosis. After operation a plaster bandage was applied and SM+INH, later INH+PAS were administered. The patient showed remarkable improvement; in three weeks the plaster was removed, active and passive physiotherapy was initiated in bed, and subaqueous exercises were soon added. After two months the patient was allowed to get up and he began to move about with crutches; by the end of five months all symptoms had vanished and the hip joint was capable of 30° painless motion. He was discharged on June 24, 1956, subsequently reported for follow-up examination every three months and



*Fig. 4-C.*  
After two years, the patient walked without crutches; support is good.



*Fig. 4-D.*  
Cartilage surface began to develop eight months following operation.



*Fig. 4-E.*  
Radiograph taken twenty-four months after operation. The tuberculous process has been healed, the cartilage is becoming stronger. The limb is rotated forward, owing to use and luxation.

continued to take INH+PAS. After the elapse of two years he could walk well without any crutches, and capacity was good (Fig. 4-C); flexion was 40°; abduction, 20°; adduction, 20°. According to radiographic evidence, the process has healed completely, articular surfaces have developed, but the limb has a rotary position (Figs. 4-D and E). In this case the result of operation is manifested by inhibition of total articular destruction and by restored motility.

#### DISCUSSION

The experience and observations of several years have furnished proof that by the help of antituberculotics and appropriate surgical intervention, articular tuberculosis can be healed, without loss of

motility by the joint. This applies chiefly to synovial processes and to cases with slight destruction discovered at an early stage and given immediate medical care.

Since the year 1955, articular resection complemented with fibrin cap arthroplasty has been performed in 20 cases of tuberculous coxitis. A follow-up period of two-three years justifies the statement that operation is worth while in every case where destruction is slight and the patient's mode of life calls for restoration of articular motility. The most significant success achieved by our operations performed to obtain mobile joints has been the healing of the tuberculous process in each case. The conditions of such results are as follows:

Surgery should preferably be performed in the regressive stage, attained by two-three months of stabilizing treatment with drugs. If the process nevertheless shows progression, surgical intervention may be undertaken earlier in order to save the joint. However, in such cases after-treatment has to be cautious, which unfortunately limits the scope of movement.

Use of the fibrin cap in arthroplasty in the presence of tuberculosis constitutes an advance. The substance is neutral to tuberculosis, does not give rise to any reaction, and the development of cartilage proceeds favourably under its protection. Radiography has shown that in three to six months the developed cartilage can be visualized by X-ray.

The extent of motion depends on the condition of the muscles and the soft parts, on cicatrization which—unfortunately—is marked in recovery from tuberculosis. This consideration has induced us to avoid plaster bandages where possible, and to employ them only in the case of intense pain.

The program of after-treatment is the most essential factor of therapy and has to be adjusted individually to the patient. Establishment of a schedule prescribing both the period and measure of stabilization, exercise, bathing, moving about with crutches, and unaided walking, demands great circumspection, and has to be supported by clinical, laboratory, and x-ray investigations. From our experiences in hip resection we have drawn the conclusion that in the case of adherence to prudent measures, regression may be expected to set in within four to six weeks.

Finally, it may be stated that, owing to modern diagnostic and therapeutic procedures, the healing of articular tuberculosis without loss of motion is possible and should be exploited to the utmost. Hip resection combined with use of the fibrin cap is also one of the methods

serving the purpose of complete restoration in some cases of tuberculous coxitis.

SUMMARY

1) The authors report on ten cases of tuberculous coxitis in which mobile joints were obtained by the use of fibrin caps in hip resection.

2) These patients have been followed-up for a period of three years. Judged by healing of tuberculosis and articular capacity, results are excellent, motility is satisfactory.

3) In every process attended by slight destruction or upon compelling indication, surgery is recommended, particularly in the case of children and young women.

4) The fibrin cap does not prevent regression of the tuberculous process, it ensures mobility, promotes the formation of cartilage and, after having fulfilled its task, is absorbed and vanishes without leaving behind any trace.

RESUME

1) Les auteurs rendent compte de dix cas de coxite tuberculeuse dans lesquels il a été obtenu des articulations mobiles au moyen d'une capsule de fibrine dans la résection de la hanche.

2) Ces malades ont été suivis pendant une période de trois ans. Si l'on se base sur la guérison de la tuberculose et la capacité articulaire, les résultats sont excellents, la mobilité est satisfaisante.

3) Dans tous les cas chez lesquels il est question soit d'une légère destruction, soit d'une indication péremptoire, l'intervention chirurgicale est recommandée, en particulier chez les enfants et les jeunes femmes.

4) La capsule de fibrine n'empêche pas la régression du processus tuberculeux, elle assure la mobilité, favorise la formation de cartilage et après avoir rempli sa mission elle est absorbée et disparaît sans laisser aucune trace.

ZUSAMMENFASSUNG

1) Die Verfasser berichten über zehn Fälle von tuberkulöser Coxitis, in denen bewegliche Gelenke mittels der Verwendung von Fibrinkappen bei der Hüftgelenksresektion erhalten wurden.

2) Diese Patienten wurden während einer Zeitspanne von drei Jahren beobachtet. Hinsichtlich der Heilung der Tuberkulose und der Ge-

lenksfunktion waren die Ergebnisse ausgezeichnet und die Beweglichkeit war zufriedenstellend.

3) In jedem Prozess, der mit leichter Zerstörung einhergeht oder bei zwingender Indikation wird der chirurgische Eingriff anbefohlen, besonders bei Kindern oder jungen Frauen.

4) Die Fibrinkappe verhindert das Zurückgehen des tuberkulösen Prozesses nicht, sie sichert die Beweglichkeit, befördert die Knorpelbildung und wird resorbiert nachdem sie ihre Aufgabe vollführt hat ohne irgend eine Spur zu hinterlassen.

#### REFERENCES

1. Galland, Sorrel, Dobson, Häberlin, Volkmann, Judet, Chigoth: *Z. Orthop.* Bd. 87. Beilagenheft. (Symp. Semmering). 1956.
2. Gerendás, M.: Surgical Application of Synthetic Substances and Bioplasts. *Acta Morph. Hung. Suppl. VII*, 25 (1956).
3. Gerendás, M.: Bioplaste und ihre Anwendungsgebiete. *Therap. Hung.* 7, 6 (1959).
4. Gerendás, M. & Biró, T.: Bioplaste und ihre klinische Anwendung. IV. Intern. Kongr. Biochem. Wien, Pergamon Press London 175 (1958).
5. Heinze, R.: *Kunststoffe in der Medizin.* J. A. Barth, Leipzig, 1955.
6. Judet, J. & Judet, R. J.: The Use of an Artificial Femoral Head for Arthroplasty of the Hip Joint. *Journ. of Bone and Joint Surg. Bd. 32/B*, S. 166 (1950).
7. Kastert, J.: Neue Behandlungsmethode der Coxitis Tbc. *Langenbecks Archiv und Zschrft. für Chir. B*, 282 (1955).
8. Kovács, P.: Fibrinkupakkal végzett arthroplastica coxitis tbc.-ben. (Arthroplasty performed with Fibrin Cap in Tuberculous (Coxitis). *Áll. Fodor József Tbc. Gyógyintézet Közleményei*, Budapest, I, 1956.
9. Schoch, J.: Zur heutigen Stand der Endoprothesenplastik der Hüfte nach Judet. *Z. Orthop.* 88 B, 502 (1957).
10. Smith-Petersen, M. N.: Approach to and Exposure of the Hip Joint for Mold Arthroplasty. *Journ. of Bone and Joint Surg.* 31-A, 40 (1949).
11. Wilkinson, M. C.: Partial Synovectomy and Curettage in the Treatment of Tuberculosis of the Hip. *Journ. of Bone and Joint Surgery.* 39-B, 66 (1957).
12. Zinner, N., Gerendás, M. & Biró, T.: A New Method of Arthroplasty. *Acta Med. Acad. Sci. Hung.* 7, 217 (1955).



50X1-HUM

**Page Denied**

Next 7 Page(s) In Document Denied

(d)

Különlenyomat

a

HAEMATOLOGIA HUNGARICA

Tomus I. Fasciculus 2.

1961. évi számából

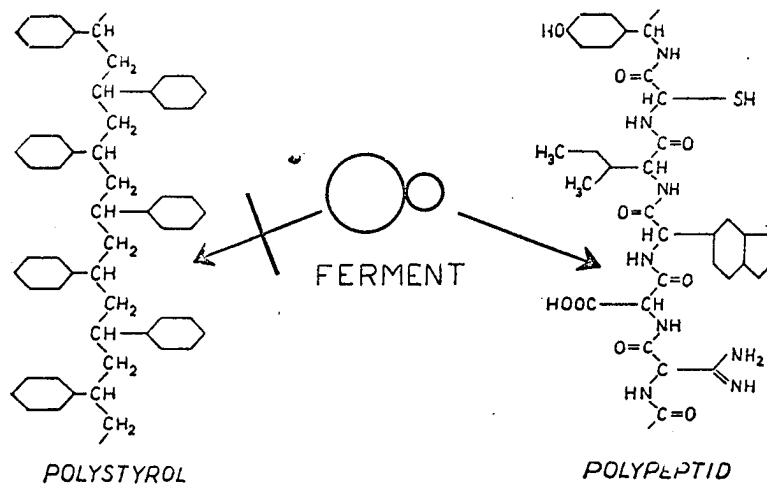
Az Országos Vértranszfúziós Szolgálat Központi Kutató Intézet  
kiadványa, Budapest.

## Tapasztalataink bioplaszt készítményekkel

DÓCZY ÁGNES

Országos Vértranszfúziós Szolgálat Központi Kutató Intézete, Budapest

A sebészetben — főleg plasticai műtéteknél — egyre nagyobb teret kapnak a különféle, prothesisként alkalmazott műanyagok. Ezen műtéteknél azonban sokszor igen fontos követelmény, hogy az alkalmazott anyag csak *ideiglenesen* maradjon a beültetés helyén. Erre a célra szolgálnak az általunk előállított ún. *bioplastok*, melyek fibrinből — tehát testazonos anyagból — készülnek. Az anyag jellemző tulajdonsága, hogy a szöveti fermentek hatására *lebomlik és felszívódik*<sup>1</sup>, tehát reoperációval való eltávolítása feleslegessé válik (1. ábra).




1. ÁBRA

*Szöveti fermentek bontó hatása. A szintetikus műanyagok molekula-láncaira hatástalanok, míg a polypeptid-kötést elbontják*


Intézetünkben 1953 óta foglalkozunk ezen anyag előállításával, főképpen *arthroplastica* céljára. Erre azért volt szükség, mert a vitallium-mal végzett eddigi műtétek csonttúlszaporulatot okoztak, és ezáltal a mozgás korlátozódott. Zinner és Gerendás a fibrin-kupak módszerét

dolgozták ki arthrosisok következtében merevvé vált csípőízületek mobilizálására<sup>2,3,4</sup>. Később Kovács<sup>5,6</sup> tbc-s megbetegedéseknél is alkalmazta kiváló eredménnyel (2. ábra). Frankl állkapocsízület mobilizálására használta fel a fibrinkupakot. Egyik esetében 18 éves férfi középfülgyulladás következtében létrejött állkapocs ankylosisát sikerült megszüntetnie<sup>7</sup>.



2. ÁBRA

B. I. 12 éves fiú tbc-s csípőízületi folyamatának röntgenképei: a) a fibrinkupak beműtése előtti lelet; b) műtét után 9 hónappal már látszik a medencecsont hiányainak kitértődése; c) műtét után 18 hónappal a csonthiány teljesen kitértődött és az ízület mozgásképes





3. ÁBRA

Fibrinkupak alkalmazása állkapocs műtéténél. a) Műtét előtti max. szájnyílás 2 mm. b) Műtét után 2½ évvel a szájnyílás 3-3½ cm

A beteg maximális szájnýtása mütét előtt 2 mm volt. Az alkalmazott fibrinsapka bemütése után  $2\frac{1}{2}$  évvel a fiú szájnýtása  $3-3\frac{1}{2}$  cm lett (3. ábra).

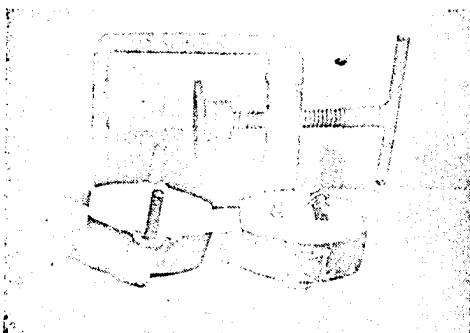
Ezen eredmények arra készttettek bennünket, hogy a bioplastokat más területeken is felhasználjuk, és előállításukat leegyszerűsítsük. Munkám során sikerült elérnem, hogy most már úgy a kupakokat, mint egyéb formadarabokat *kézipréseléssel* állítunk elő. A következőkben szeretném a bioplastok előállítási módját röviden vázolni és újabb felhasználási területeit ismertetni.

Az előző évek munkájától eltérően a bioplastokhoz szükséges fibrinport a *Cohn I-es* frakcióból nyerjük és laboratóriumunkban préseljük. Az eljárás előnye, hogy egyszerűségénél fogva bármely laboratórium elkészítheti a kívánt formákat (4., 5., 6. ábra).




4. ABRA

Fibrinkupakok préselése fémformával. a) Fibrinpor betöltése. b) A kész kupak kiemelése



5. ABRA

Gipszminta készítése




6. ABRA

Gipszmintázással készített bioplast csavar


Préselés után a mintadarabokat a megfelelő kémiai kezelésnek vetjük alá, ugyanis ezzel az anyag felszívódási folyamatát mintegy *időzíteni* tudjuk. Felhasználás előtt az idomok *autoklávban sterilizálhatók*. A különböző formadarabokat a 7. ábrán mutatjuk be.

A sebészeti osztályokkal végzett együttműködésünk azt mutatta, hogy a fibrin megfelelőnek mutatkozik a felszívódó műanyaggal szemben támasztott sebészeti igények kielégítésére.



7. ABRA

Bioplast formadarabok: a) kupakok, b) csövek, c) tömb, d) csavarok, e) lemez



8. ABRA

Fibrinhálóval megerősített fibrinlemez behelyezése sérv műtétnél

*Dragon* (Szentés) fibrinműveinket alkalmazta *choledochus pótlására* jó eredménnyel. A vastagfalú fibrinmű beültetése lehetővé tette az epelefolyás zavartalanságát. Egy esetben hosszú ideig fennálló *choledochus sipolyt* is szájadzatatott vékonybélbe szintén eredményesen.

Fibrinműveket II. és III. fokú égéseknél használtak fel a sebfelület borítására. Megfigyelték, hogy a II. fokú égéseknél hamarabb történt a hámosodás az alap felől, tehát a mű a regenerációt mintegy elősegítette.

*Fröhlich* és *Ambrózy* (Gyula) szintén *choledochus pótlására* használtak fibrinművet, a szokásos *Kehr*-cső helyett.

Szövetdefectusok pótlására igen jónak bizonyult a fibrinművel átszőtt bioplastlemez. *Hollósy* (Kalocsa) alkalmazta *recidivált lágyéksérv* eseteiben (8. ábra). Az anyagot jónak tartja, mert mint homiootransplantátum nem okoz carcigonén hatást és elősegíti az ellenálló hegszövet gyors kialakulását, s ezáltal újabb recidiva már nem jött létre.

Legújabb kísérleteinkben *Biróval* (Orthopaed klinika, Budapest) *invarratok védelmére* végeztünk állatkísérleteket, hogy így biztosítsuk az inszalag funkcionális működését. A tapasztalat és a kontrollon végzett kísérletek ugyanis azt mutatták, hogy fibrinmű védelme nélkül a sértett ín letapadt.

#### Összefoglalás

A fibrinműből készült ún. *bioplastok* mint felszívódó formadarabok bizonyos orthopaed és általános sebészi műtéteknél az eddigi anyagokkal szemben sokkal jobban megfelelnek a követelményeknek, mivel a reoperáció kiküszöbölésével a beteget megkíméljük egy második, komoly beavatkozástól. Ezenkívül megfigyeltük, hogy a bioplastok a regenerációra is kedvező hatást fejtenek ki. Ismertettük a bioplastok eddigi alkalmazási területeit és beszámoltunk néhány újabb eredményről.

### Clinical Use of Bioplastic

#### A. DÓCZY

In surgery — and mainly in plastic surgery various synthetic substances employed as prostheses find an ever increasing use. However, in some operations it is an important requirement that the used substance remains only temporarily on the site of the implantation. This purpose is served by our bioplast preparations which are made from fibrin, thus a body-identical substance. The characteristic property of bioplasts is that they decompose and absorb on the effect of tissue ferments and their reoperative removal is thereby unnecessary.

Bioplasts were prepared heretofore mainly for the mobilization of hip-joints and mandible joints, dural replacements, for the preservation of nerve sutures. The most recent preparations are: reticular fibrin-net embedded in fibrin-film for hernial or peritoneal operations, fibrin-tubes to be applied in choledochal plastics and the preparation of choledochal fistula, fibrin-film to cover epithelial defects in cases of II. and III. rate burns, fibrin tubes for the protection of tendon sutures.

Cooperation with surgical departments established that fibrin proves to meet the demands required of absorptive synthetic substances in surgical practice.

## Опыт применения препаратов биопласта

А. ДОЦИ

В хирургической практике, в особенности при пластических операциях, различные искусственные материалы, использованные в качестве протезов, находят все более широкое поле применения. При отдельных операциях, однако, часто важным требованием является то, чтобы применяемый материал оставался на месте имплантации лишь временно. Для этой цели служат выработанные нами биопласты, составленные из фибрина, значит, из вещества однородного с телом. Биопласты обладают той характерной особенностью, что они, под влиянием тканевых ферментов, разлагаются и всасываются и, поэтому, нет надобности в их удалении путем реоперации.

Биопласты до сих пор производились нами для мобилизации тазобедренного сустава и суставов челюсти, для замены твердой мозговой оболочки, для защиты нервных швов и т.д. Наши новые препараты следующие: фибриновая сетка, вложенная в фибриновую пленку для операций грыж и брюшной стенки; фибринные трубочки для пластики желчного протока и создания свища желчного протока; фибринные пленки для покрытия областной, лишенной эпителия при ожогах 2 и 3 степени; фибринные трубочки для защиты сухожильных швов, и фибринные стерженьки для оперативного лечения повреждений слезного канальца.

Наше сотрудничество с хирургическим отделением показывает, что фибрин удовлетворяет хирургическим требованиям, предъявленным по отношению к всасываемому искусственному материалу.

### Irodalom

1. *Afra, D., Bagly, D. und Gerendás, M.*: Experimentelle Untersuchung der Resorption von Fibrinfilmen und ihre Anwendung in der neurochirurgischen Praxis. Acta Med. Acad. Sci. Hung. 11, 1 (1957).
2. *Zinner N., Gerendás M. és Biró T.*: Az ízületképzés új módja. Orv. Hetil. 95, 932 (1954).
3. *Zinner, N. and Biró, T.*: A new method in arthroplasty. Rheumatism. 15, 69 (1959).
4. *Gerendás, M. und Biró, T.*: Bioplaste und ihre klinische Anwendung. IV. Intern. Kong. Biochemistry, Wien, Pergamon Press, London, 1958. 175.
5. *Kovács P. és Gerendás M.*: Arthroplastica coxitis tbc-ben fibrinkupakkal. Orv. Hetil. 101, 1387 (1960).
6. *Gerendás, M.*: Resorbierbare Endoprothese aus Bioplast. Radiol. Diagn. 1, 250 (1960).
7. *Gerendás, M.*: Bioplasts and their use in surgery. Therap. Hung. 7, 6 (1959).



# Therapia Hungarica

Volume 7 1959 1-2

C.

From the Central Research Institute of the National Blood Donor Service (Director: Dr. Z. Hollán), Budapest

## BIOPLASTS AND THEIR USE IN SURGERY

Prof. M. GERENDÁS

### Viewpoints in the Use of Metals and Plastics in Surgery

Metals and synthetic plastics have for long been employed in the various branches of surgery for the repair of tissue defects or for the promotion of healing: for example, to replace bone after head injury, to nail fractured bones, etc.

Such materials must have certain properties. They must not irritate tissues, must remain without corrosion in the body, must be sterilizable, etc. The metals and plastics now in use usually meet these requirements (1).

However, recent advance in surgery has demanded further improvements. There are now several operations in which the implanted graft is to remain in place only temporarily to fix, isolate some part, or to act as a guide, because in its presence the organism's capacity for regeneration and the morphogenetic influence of function makes the development of new tissue possible. It is known for example that the fusion of articular surfaces from which the cartilage has been removed can be prevented by the aid of metallic or plastic cups under which new cartilage will form if the joint is properly used. In cases of fracture, union will proceed smoothly after bone marrow nailing. Likewise, tissue neogenesis ensuring function may take place in soft tissues, for instance when a defect in the bile duct is repaired by guiding canalization with a suitable prosthesis, e. g. a perlon tube (2). However, once reparation is complete the implant becomes superfluous or even noxious and is eventually ejected. For this reason in many cases it has to be removed by another operation.

These considerations have induced us to develop and manufacture a material that would promote healing by its presence in the organism but would be absorbed completely, and disappear without a trace after regeneration has been completed.

### Absorbable Surgical Plastics (Bioplasts)

In our efforts at producing absorbable surgical plastics, attention was focussed on blood proteins, mainly on fibrin. We found that fibrin can be isolated from plasma by a relatively simple procedure and can be converted into a plastic material suitable for use in surgery.

The use of proteins is significant, because the proteolytic enzymes of the cells are capable of breaking up the peptide

bonds of proteins, but are ineffective on the linkages (e. g. methylene bonds) of synthetic plastics. This difference in behaviour determines the use of the two kinds of prosthesis. Synthetic plastics remain in place indefinitely, whereas the surgical moulds prepared from natural substances (protein) are absorbed and can be used when their presence is required temporarily. The latter are called *bioplasts*.

Bioplasts are no substitutes for synthetic plastics, but, being absorbable, may be used in special fields of surgery, and open up entirely new possibilities (2).

### Preparation of Bioplasts

Absorbable moulds can be prepared from various blood proteins (albumin, fibrin). By the method we have developed, fibrin can be isolated with high purity, on an industrial scale (3).

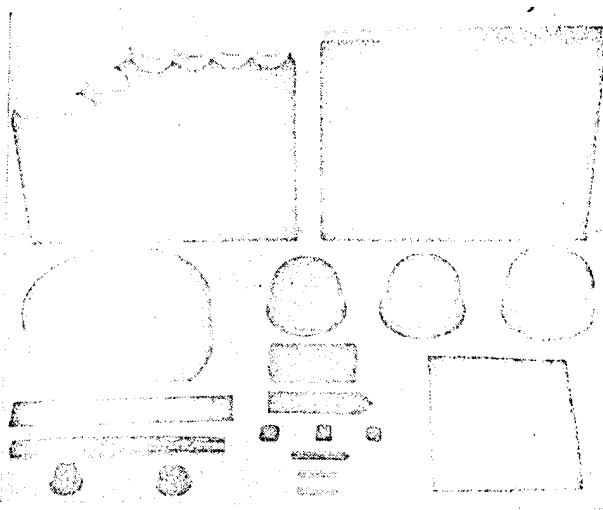


FIG. 1.—Bioplast moulds: tubes, sheaths, nails, plugs, cups.

Crude fibrin is made into flour-fine dry powder. To this are added plastifying substances, then the moulds of desired shape are formed under high pressure and heating, by means of a pressing machine. Subsequently the moulds are bathed in chemicals to make them hard and resilient, on the one hand, and to adjust absorption time to the actual need, on the other. Finally, chemical treatment makes the mould less hydrophilic, preventing its substantial swelling during sterilisation or in the body (4, 5, 6).

We started work in this field at the Pharmaceutical Research Institute (1951—53). The method was then further developed in the Central Research Institute of the National Blood Donor Service (Budapest, 1955—58) and the moulds are produced there.

By the above method moulds of various shapes: tubes, sheaths, rods, nails, plugs, cups, etc. may be obtained (fig. 1).

At present, bioplasts are made of human fibrin. It is known, however, that after suitable purification and heat treatment, fibrin products made of bovine or pig plasma may also be used in clinical practice (7, 8, 9).

#### Properties of Bioplasts

In appearance bioplasts are similar to synthetic plastics but their consistency can be altered greatly by the addition of plastifying substances and chemical treatment. In this way the preparation can be made to meet the anatomical and histological requirements of the actual operation.

The fibrin grafts may be regarded as homeoplastic materials which contain no ingredients or toxic components noxious to tissues. Their greatest advantage lies in being broken down through the proteolytic enzymes produced by the cells and in being absorbed completely (10).

The characteristic properties of bioplasts are summarized in table I and table II.

TABLE I—CHARACTERISTIC PROPERTIES OF BIOPLASTS

Consistency	Resilient mould, similar to cartilage in hardness
Colour	Yellowish-brown, transparent
Smell	Reminiscent of broth
Specific gravity	1.22 to 1.30
Species specificity	No antigenic properties
Rate of absorption	1 to 6 months, depending on chemical treatment
Sterilizability	Sterilizable in autoclave at 120° C, 1.2 atm.

TABLE II—MECHANICAL PROPERTIES OF BIOPLASTS

Compressive strength	140 to 760 kg./square cm.
Tensile strength	110 to 830 kg./square cm.
Bending strength	95 to 350 kg./square cm.
Impact-bending strength	10 to 30 cm.kg./square cm.

#### Various Uses of Bioplasts

Our preparations are now in use in various fields of surgery. Although statistically the data obtained hitherto are not too numerous, it seems justified to present here a brief survey of some of the results achieved by the use of bioplasts.

#### Protection of Peripheral Nerve Sutures by Fibrin Sheath

End-to-end sutures are often unfeasible in neurosurgical practice. In such cases it should be ensured that




FIG. 2.—Fibrin sheath for the protection of peripheral nerve suture, 13 days after grafting. Cross section, magnified about 60 times. The connective tissue coat around the fibrin tube is only loosely attached to the epineurium (11).

the nerve stumps unite through the growing axons and that connective tissue should not overgrow the regenerating nerve.

Áfra et al. (11) made preliminary studies in cats.

A piece of 5 to 10 mm. length was excised from the sciatic nerve, the stumps were pulled into a previously prepared fibrin sheath and were sutured (fixed) to the wall of the sheath so that the two ends were separated by a distance of 10 to 12 mm. The fibrin sheaths employed were 3 to 4 cm. long, had an internal diameter of 3 to 3.5 mm. and a wall thickness of 0.6 to 0.9 mm.

The animals were killed 4 to 240 days later and the area of operation was examined histologically. Microscopic studies showed that at first the fibrin sheath was covered by a coat of connective tissue (fig. 2), then the proteolytic enzymes began to break down the sheath, which was absorbed in about four to five months. Thereafter the nerve lay free in the muscular interspace.

As regards the efficacy of the method, it is important that the connective tissue coat around the fibrin sheath was only loosely connected with the epineurium and did not interfere with regeneration.

In these operations the fibrin sheath acts as an itinerarium for the axons growing from the proximal stump and bridges over the distance between the two stumps. Moreover, it creates favourable conditions for regeneration and prevents the formation of adhesions between the lesioned nerve and adjacent tissues.

After the successful animal experiments, Áfra et al. introduced the method into clinical practice, with full success in the 10 cases reported on thus far. Regeneration was excellent, even when there was a distance of 10 mm. between the nerve ends in the fibrin sheath after operation. In one case the glass splinters causing the nerve lesion could not be completely removed. At reoperation eight months later in order to remove the foreign bodies it was found that the fibrin sheath had been absorbed and the nerve lay free in its environment. In a few cases sterile seroma was formed, but this did not interfere with the success of operation.

Systematic clinical and electromyographic studies in the course of healing showed that regeneration was complete and function highly satisfactory. The method has been in continuous use since publication of the report.




FIG. 3.—Recanalization of obliterated uterine horn by operation using fibrin tube. Radiographic appearance of rabbit uterus filled with lipiodol four weeks after implantation of fibrin tube. Morphological and functional repair is complete (13).

Similar considerations have led Biró et al. (12) to use fibrin sheaths around tendon sutures, to ensure free mobility of tendon among the tissues.

#### Fibrin Tubes for Canalization

Patat and Bagdy (13) applied small-calibre fibrin tubes in their studies on the recanalization of the Fallopian tube. At first they carried out model experiments on rats, rabbits, and dogs, trying to recanalize artificially obliterated uterine horns. In the preparatory operation the horn was opened, electrocauterized, and united by suture. At reoperation, two weeks later when obliteration was ascertained,




FIG. 4.—Connective tissue coat rich in fibres seven months after implantation of fibrin tube for the repair of common bile duct. Only traces of the fibrin tube are visible.

the adhesion was severed and a fibrin tube inserted into the horn. The tubes employed had an internal diameter of 1 to 1.5 mm. and a wall thickness of 0.2 to 0.3 mm.

The fibrin tube ensured fluid flow in the horn and, in contrast with the controls, prevented the development of hydrometra. The internal wound surfaces epithelialized rapidly and the tube, as it were, guided the growth of a new tissue structure. Even when obliteration was extensive, the mucosa was found to grow over the lesioned area, under the protection of the tube. Patency of the lumen is illustrated in fig. 3. Clinical use of the method is in progress.

Pataky et al. (14, 15) have used fibrin tubes for the repair of the common bile duct. In experiments, common bile duct repair was performed on 16 dogs. The fate of the inserted tubes was examined between six weeks and eleven months after operation. Microscopic studies revealed no change in the heart, spleen, kidney, lungs, or brain, and the peritoneum showed no sign of irritation. There was no local inflammation around the tube graft. During the first five months a small number of leucocytes that appeared around the tube took part in the phagocytosis of fibrin.

Absorption of the tubes was uneventful. In the third month the tubes dissociated into fibres, then broke up. Only residue of fibrin was detectable in the seventh month (fig. 4). Finally, by the eleventh month even traces of the fibrin tube had disappeared.

The rôle of the common bile duct was taken over by a tube of connective tissue which had formed around the fibrin tube graft, as could be ascertained by the aid of contrast medium and radiography. Unfortunately, canalization was imperfect, presumably because of the strangulation and irritation exerted by the silk ligation on the tissues. It has therefore been concluded that the quality of the thread used for ligation and the technique of operation are of paramount importance.




FIG. 5.—Two years after vitallium cup arthroplasty. Bony proliferation severely restricting motion is visible around the metal cup.




FIG. 6.—Fibrin cup for hip joint arthroplasty in dogs, shaped after a model femoral head (22).

Realizing this, Fröhlich and Ambrózy (16) used 0 catgut for ligature in clinical trials, since catgut is absorbed and thus cannot cause lasting strangulation or stricture. They used fibrin tubes when the defect in the common bile duct amounted to 2 to 3 cm. between the two ends and this gap could not be bridged over by mobilization. Instead of the formerly employed rubber or plastic prosthesis they introduced a fibrin tube into the stumps, suturing a cuff of soft tissue onto the surface of the tube. The tubes used were 3 to 4 cm. long, 5 mm. in internal diameter, with a wall thickness of about 1 mm. To coat the tube with surrounding tissues is essential from the point of view of regeneration, because canalization starts from these tissues, along the fibrin tube.

The patients thus operated have no complaints one year after surgery.

#### Fibrin Cups in Arthroplasty

One of the chief aims in orthopedic surgery is the formation of new joints by restoring mobility of




FIG. 7.—Hip joint 50 days after operation. The articular space is absolutely free, there is no trace of fibrin any longer (22).




FIG. 8.—Microscopic appearance of newly formed islets of cartilage on articular surface (22).

joints ankylosed owing to pathological processes or congenital abnormality. If the joint is exposed surgically, the cartilage removed and arthroplasty performed, this will usually fail to bring about the desired results, partly because the contact and shift over one another of the denuded surfaces produces serious pain and partly because bony union is almost certain to ensue.

So far, the greatest advance in this field was represented by the vitallium cup method of Smith-Petersen (17). This prevents bony union, makes early passive, then active, comparatively painless exercise possible, which is important for the neogenesis of cartilage.

Krompecher (18), Gibbson and Williams (19), then Rabl (20) presented morphological evidence to show that cartilage was formed on joint ends when moved under loading. The same was proved in two cases described by Zinner and Biró, in which reoperation was necessary because of dislocation. Thus the cup, under whose protection the cartilage develops, makes itself unnecessary.

However, vitallium cup arthroplasty has serious disadvantages as well. The mobility of the joint is not normal, because the vitallium cup moves separately in the acetabulum and the femoral head moves separately in the cup. Smith-Petersen himself reported (21) that, although by no means heteroplastic, the mere presence of the vitallium cup caused bony proliferation. Also Zinner and Biró stated that the newly formed bone (neostosis) slowly surrounds the cup, restricts motions and the joint becomes painful (fig. 5). Hence in such cases the cup is not only superfluous, but even detrimental for articular function. It is seldom feasible to remove it, because reoperation for the purpose exposes the patient to equally great stress again.

The bioplast cups recommended by Zinner and Biró have none of the disadvantages associated with




FIG. 9.—Appearance and cross section of fibrin cup for hip joint arthroplasty in man.




FIG. 10.—Fibrin cup placed on femoral head during operation.

heterologous material. These authors first tried such cups in the hip joint of dogs (22). The cup was modelled after a femoral head (fig. 6). At operation the cartilage was removed from the femoral head.

The experimental animals were sacrificed 28 and 50 days after operation. At 28 days the cup had become thinner, but was still in place. In 50 days the fibrin cup, having produced the desired effect, was absorbed (fig. 7). The joint space was absolutely free and the joint was freely movable. Thus the disappearance of the prosthesis ensures physiologic repair and also precludes any deformation of bone caused by the presence of heterologous material.

On the articular surface microscopic study showed islets of newly formed cartilage that facilitated mobility of the newly formed joint (fig. 8).

The dogs began to walk shortly after operation, and tolerated stress on their limbs without any sign of pain. It is remarkable that if the animals were not allowed to walk, only a fibrous collagenous mass, but no hyaline cartilage, developed, in complete agreement with the statements made by Krompecher (18) in conjunction with cartilage formation after arthroplasty.

As a result of the evidence obtained in animal experiments, fibrin cups have been in clinical use since 1955 (23, 24, 25). Most patients had been bed-ridden before operation, being unable to move their hip joints.

After studying the anatomy of the human hip joint, we prepared cups nearly hemispherical in shape, 51,

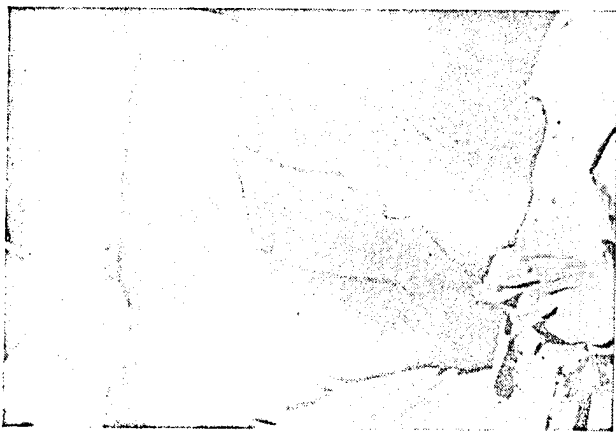

FIG. 11.—After operation the limb is moved to ascertain whether the femoral head is moving in the acetabulum.




FIG. 12.—Mobility of a 32 year old female patient 3 1/2 years after fibrin cup arthroplasty.

47, or 44 mm. in external diameter (fig. 9). The wall thickness was 2.5 mm. on the top of the hemisphere (where exposure to weight-bearing is greater), 1.5 mm. at the side, with slightly thicker margin. The various sizes were destined for use in males, females, and children, respectively.

At operation the hip joint is exposed, the femoral head is dislocated from the acetabulum, the uneven surface is smoothed. Then the sterilized fibrin cup is pulled on the femoral head, so that it should fit tightly on the surface (fig. 10). The fibrin cup, easily put in place, is not fragile, and fits well on the newly formed articular end. Finally, the femoral head is brought back into place in the newly formed acetabular articular cavity, then the wound is closed. With the patient still under general anaesthesia, the limb is moved passively to ascertain that the femoral head is in fact in the acetabulum (fig. 11).

Exercise is begun ten to twelve days after operation. After three or four weeks the patient is allowed to get up; he walks with crutches for half a year, and then gradually exposes the operated limb to weight-bearing.

Zinner and Biró (23, 24, 25) reported on 9 cases of hip joint arthroplasty. The pathological conditions for which surgery had to be performed were congenital luxation, chronic polyarthritis, deforming osteoarthritis of the hip joint, ankylosing spondylitis (von Bechterew's disease), and reoperation after vitallium arthroplasty. Except for the two cases of ankylosing spondylitis, the results of surgery were good. The beneficial effect of fibrin cup arthroplasty is illustrated by the case of Mrs. M. I., aged 32, with arthrosis (osteoarthritis) coxae (fig. 12).

Shortly after operation the patients showed remarkably free joint mobility and had almost no pain. Later there was no pain on walking. When passive exercise is begun, flexion may reach 70 to 90 degrees, abduction 30 to 40 degrees. Passive mobility decreases slightly after four to five weeks, but increases again later. After operation some patients walk without wobbling, with good stability, others show a slight Trendelenburg sign.

In the cases of ankylosing spondylitis mobility was satisfactory and painless in the early phase, but soon a restriction of motion became evident and finally only minimal flexion remained. The basic condition appears to be responsible for failure in these cases.

Surgical mortality was nil, suppuration did not occur. In a few cases seroma formation lasting one to two weeks was noted, but it proved to be sterile

throughout and did not interfere with the success of operation.

Fibrin prostheses have been used by authors in 7 cases in operations other than hip joint arthroplasty, including such conditions as radio-ulnar synostosis, hallux valgus, state after poliomyelitis, ankylosis of the knee or of the elbow joint. The results were good, function being excellent as late as 3 to 3 1/2 years after operation.

On the basis of these results, Zinner and Biró believe that fibrin seems to have fulfilled the hopes attached to it in arthroplastic operations and is the best prosthesis hitherto employed. They emphasize, however, that the absorbable prosthesis is but one essential requirement in arthroplasty and that the regenerative power of the body, postoperative treatment, neogenesis of cartilage, and so forth are important factors in recovery and should remain the subject of further study.

#### Fibrin Cup Arthroplasty in Tuberculous Coxitis

In articular tuberculosis for a long time there was a general tendency to immobilize the affected joint, allowing it to ankylose, or when this did not take place arthrodesis was performed. The advent of antibiotics encouraged the hope to preserve joint mobility, but unfortunately the arthroplasties with synthetic materials mostly produced poor results. Attempts have therefore been made to use fibrin cups also in such conditions.

Since 1955, Kovács has performed fibrin cup arthroplasty in 18 cases of tuberculous coxitis (26, 27) with fairly favourable results. However, the joints were less freely movable than expected, presumably because postoperative exercise had been too cautious and because tuberculous tissues are known to heal with scar formation. On the other hand, the patients could return to work, had neither complaints nor symptoms and can be considered cured. Arthrodesis was not performed. In two instances ankylosis developed; no further operation was undertaken in these cases.

At first indications were rigidly restricted, but in view of the good results the field of indications has been widened. Whenever there is a pathological process causing minor damage to the hip joint, fibrin cup arthroplasty is one of the possibilities at operation, and is performed if the condition of the affected area permits it.

Pretreatment consists in complete rest and administration of antituberculous over a period of one to two months. At operation, Smith-Petersen's incision and sparing resection are applied. The defects caused by destruction are filled with a mixture of fibrin powder and blood cake, or with ground bone, and after shaping of the joint surfaces the fibrin cup is pulled

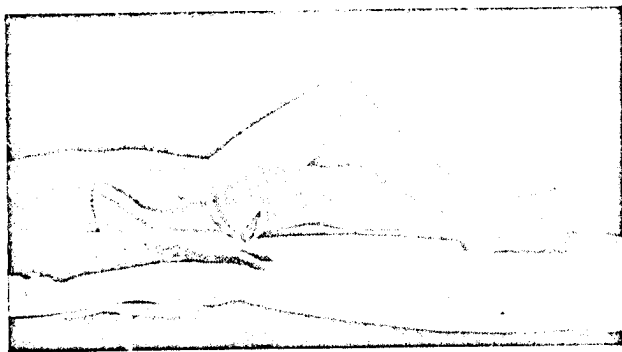




FIG. 13.—Appearance of a 12 year old boy with tuberculous coxitis prior to arthroplasty. Motions restricted and painful.



(a)

(b)



(c)

(d)

FIG. 14.—Radiographs of the hip joint of the patient shown in fig. 13. (a) Before operation. Extensive and deep tuberculous changes in the pelvis. (b) One month after operation. Antibiotics brought the process to a standstill, the joint remained movable. The fibrin cup still present in the joint gives no x-ray shadow. (c) 7 months after operation. The bone defect is disappearing. (d) 2 1/2 years after operation. The destroyed bone has regenerated, the tuberculous affection has healed (27).

on the head of the femur. The joint is drained, then through the drain blood is sucked off and hyaluronidase + hydrocortisone + streptomycin + INH are injected over a period of four to fourteen days. Immobilization in plaster or extension bandage is employed for three to four weeks.

Initiation of passive and active exercise depends on the outcome of surgery and on the histologic findings. Exercise is begun one month after surgery when the activity of the process has been only slight, and two months after surgery when it has been more severe before operation. Later sub-aqua exercise, walking with crutches, etc. follow.

In general, surgical results are good as regards healing of tuberculosis and weight-bearing, and satisfactory as far as mobility is concerned. When the operation has been decided upon after careful consideration and where pre- and postoperative management has been adequate, mobility does not interfere with healing. Even tuberculous tissues tolerate the presence of the fibrin cup well, and, as shown by radiography, sufficient cartilage is formed under the cup in three to six months. As an illustrative example, we present the case of B. L., a boy aged 12 years (fig. 13, 14, 15).

#### Fibrin Cup Arthroplasty of the Mandibular Joint

In rabbit experiments Frankl and Guoth resected the cartilage from the mandibular joint, pulled a




FIG. 15.—Mobility of the patient 3 years after fibrin cap arthroplasty of the hip joint.

fibrin cap of suitable size on the denuded articular surface, and found that hyaline cartilage developed on the articular surface. Frankl (28) introduced the method into oral surgery. Of his material, we present a case of ankylosis of the left mandibular joint (H. I., male, aged 18 years). At the age of 5 years, scarlet fever with purulent otitis media developed. An operation was performed, yet the process spread to the mandibular joint and caused ankylosis. The fibrin cap employed was shaped after a model mandible (fig. 16). The patient had undergone two operations previously, but he could not open his mouth to more than 3 mm. (fig. 17a).

After exposure, the mandibular joint was mobilized, a small finger-sized process was shaped on the ascending part of the coronoid process and the fibrin cap was pulled on it. Immediately after operation the patient opened his mouth spontaneously to 2 cm., 2 1/2 years later to 3.5 cm. (fig. 17b).

The use of the fibrin cap interpositum in ankylosis of the mandibular joint is a simple and promising procedure.

#### Use of Bioplasts in Other Branches of Surgery

Animal experiments are in progress with a view to extending the indications for the use of bioplasts. Gergely et al. (29) apply fibrin plugs to seal the bronchial stump after lobectomy. They start out from the consideration that after lobectomy the closure of the stump usually causes destruction of the cartilaginous tube and, though such cases are rare, the suture may give way. If, however, a bioplast plug of suitable size and shape is placed in the lumen, hermetic sealing is ensured without destroying the cartilaginous wall. The plug can be held in place by sutures (catgut) in its margins.

Five dogs were lobectomized in this way. One animal died of postoperative complications, but the remaining four recovered, with the bronchus sealed without complication.

Remete et al. have used fibrin plates to repair chest wall defects (30, 31) in dogs.


Defects varying in size from 5×3 to 10×8 cm. were created in the chest wall. Two of the 7 animals succumbed to operation, the rest made uneventful recovery.



FIG. 16. Fibrin cap for mandibular joint arthroplasty, shaped after a model mandible.

The animals were killed two to four months after operation. It was found that in the operative area a smooth, shiny surface, pleura-like in appearance, with a fine scar tissue outline, had developed in every case (fig. 18). The connective tissue formed in place of the fibrin film is finer in structure and conforms histologically more closely to the original than that resulting from the use of skin flaps.

The fibrin plate (film) easily breaks at sutures. This difficulty is overcome by strengthening the margin with fibrin fibres pressed into it.



(a) (b)  
FIG. 17. (a) Mandibular joint ankylosis in a male aged 18 years. Maximum range of mandibular motion 2 to 3 mm. (b) 3 1/2 years after operation. Mandibular motion painless.

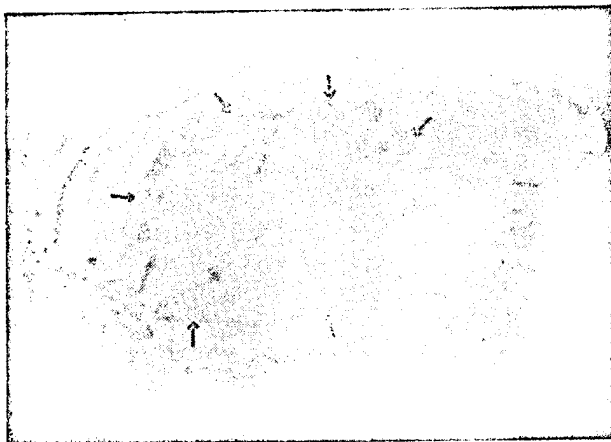


FIG. 18.—Repair of chest wall defect under fibrin film protection. The arrows mark the regenerated pleural surface (31).

Absorbable prostheses facilitating nailing or screwing together of fractured bones offer obvious advantages, because they do not remain in place as foreign bodies after the healing of fracture.

Berentey and Kalabay (32) wanted to elucidate whether fibrin prostheses retain stability and do not give rise to unpleasant reactions in the tissues.

They used rats in their experiments, employing 20 mm. long, 1.5 to 2 mm. thick fibrin nails, triangle-shaped in cross section, with pointed tips. The femur was pierced by a dentist's drill and the nails were driven into the marrow-cavity, through the trochanter.

Four weeks after implantation the nails were absolutely intact, and neither the bone nor the bone marrow cavity showed any sign of absorption (fig. 19a).

At eight weeks the peripheral areas of the nail had been attacked by proteolytic enzymes, but the main mass was still intact (fig. 19b).

At twelve weeks the nail had disintegrated, split into small fragments and lost its stability (fig. 19c); thus lysis proceeded fast between the 8th and 12th weeks. These data indicate that the prostheses (nails) remain in place long enough to keep the




FIG. 19.—Fate of fibrin nail (prosthesis) in medullary cavity (a) 4 weeks after implantation. No sign of absorption. (b) At 8 weeks, signs of lysis can be seen at the periphery, but the main mass of the fibrin nail is still intact. (c) At 12 weeks the nail has disintegrated and most of it has been absorbed.

fracture ends together and to allow time for ossification. It must be pointed out that absorption time may be further prolonged by chemical treatment.

The presence of the prostheses (nails) had no untoward effect either on the bone marrow cavity or on spongy bone.

\*

Besides the above discussed uses of bioplasts, many other possible fields of application are being studied and new suggestions for their use in the various branches of surgery are made practically day by day.

#### Discussion

In this report we have dealt with the results already obtained by the use of bioplasts.

We are aware of the fact that our method is far from being perfect. Nevertheless, some promising initial results are already on hand. The failures (for example the restriction of motion in ankylosing spondylitis after apparently successful arthroplasty and the stricture of the common bile duct caused by ligation with silk) seem to be due to erroneous indication or imperfect surgical technique rather than to inadequacy of the fibrin graft. Further work is necessary in order to establish clear-cut indications, to improve surgical techniques, and to specialize the properties of absorbable bioplasts. At any rate, there is positive evidence that absorbable bioplasts are a reality and can be used as prostheses.

We are convinced that the bioplasts will stimulate extensive practical and theoretical research. Fibrin, which has been placed in the centre of our practical research, plays an important rôle in regenerative processes and thus the experience obtained may be useful in theoretical work concerned with the latter.

It would be a valuable reward of our work if biochemists and surgeons showed interest in bioplasts.

#### Summary

Synthetic plastics are being used extensively for permanent repair of tissue defects. Advance in surgery, however, has made it necessary to develop moulds that remain in place only until tissue regeneration is completed.

Preparations made of proteins, first of all fibrin, have been found to be most suitable for such purposes, the peptide bonds of protein molecules being broken up by the proteolytic enzymes of the cells. We have succeeded in preparing moulds of fibrin which, by their shape and stability, ensure a proper course of regeneration; then, giving place to normal growth, they disappear completely from the area in which they had been implanted. Thus synthetic plastics may be used when the prosthesis should remain in place permanently, and the protein moulds we have developed will be the means of choice when absorption of the graft after a time is desirable. The latter type of grafts have been named *bioplasts*. The bioplasts open up entirely new possibilities in surgery.

Bioplast moulds have been tried out with success in many fields of surgery. Sheaths for the protection of nerve sutures, tubes for the recanalization of the Fallopian tube and for the repair of the common bile duct, cups for hip and mandibular joint arthroplasty, plugs for sealing bronchial stumps, films, plates for the repair of defects in the chest wall, etc. have been used to good advantage.

The results obtained are satisfactory and suggest that bioplasts are useful aids when absorbable grafts are required in surgery.

#### REFERENCES

- (1) Heinze, R. (1955) *Kunststoffe in der Medizin*. Verl. A. Barth, Leipzig.
- (2) Gerendás, M., Biró, T. (1958) *Bioplaste und ihre klinische Anwendung*. Vortrag. IV. Intern. Biochem. Kongr. Wien. Pergamon Press Ltd. London.
- (3) Gerendás, M., Bagdy, D. Method for the Preparation of High-Purity Fibrinogen. Hungarian Patent No. 141,438.
- (4) Török, K. (1956) Preparation of Fibrinoplast Moulds for Use in Surgery. Diploma Work. Budapest, Műszaki Egyetem.



- (5) Gerendás, M., Bíró, T. Method for the Preparation of Absorbable Surgical Moulds. Patent registered.
- (6) Gerendás, M., Dóczy, A. (1957-1958) In Press.
- (7) Bagdy, D., Szilágyi, T. (1953) *Experientia*, 9, 163.
- (8) Szilágyi, T., Bagdy, D. (1955) *Zschr. f. Immunitätsforschung u. exp. Therapie*, 112, 403.
- (9) Glynn, J. H., Richardson, J. H. (1946) *Immunology*, 53, 143.
- (10) Bagdy, D., Áfra, D., Gerendás, M. (1956) *Acta Morph. Hung. Suppl.* VII, 25.
- (11) Áfra, D., Bagdy, D., Gerendás, M. (1957) *Acta Med. Acad. Sci. Hung.* 9, 1.
- (12) Bíró, T., Gerendás, M. In Press.
- (13) Patat, P., Bagdy, S. (1957) *Magy. Néorv. Lapja*, 20, 347.
- (14) Pataky, Z., Gergely, R., Mérei, G., Csillag, A., Gerendás, M. (1956) *Acta Morph. Acad. Sci. Hung. Suppl.* VII, 25.
- (15) Pataky, Z., Mérei, G., Csillag, A., Gerendás, M. (1957) *Kísérlet. Orvostud.* 9, 462.
- (16) Fröhlich, O., Ambrózy, L. Personal Communication.
- (17) Smith-Petersen, M. N. (1939) *J. Bone and Joint Surg.* 21 A, 269.
- (18) Krompecher, I. (1938) *Anat. Anzeiger*, 87, Ergb. p. 43.
- (19) Gibson, A., Williams, T. (1951) *J. of Bone and Joint Surg.* 33 B, 119.
- (20) Rabl, R. (1952) *Z. f. Orthopädie*, 82, 468.
- (21) Smith-Petersen, M. N. (1948) *J. Bone and Joint Surg.* 30 B, 59.
- (22) Zinner, N., Gerendás, M., Bíró, T. (1955) *Acta Med. Acad. Sci. Hung.* 7, 217.
- (23) Zinner, N. (1956) *Acta Morph. Acad. Sci. Hung.* VII, 15.
- (24) Zinner, N. 3rd International Congress for Orthopaedics, Torino, 1957.
- (25) Zinner, N., Bíró, T. *Rheumatism.* (In Press.)
- (26) Kovács, P. (1956) Publications of State Institute József Fodor for TB, 1, 215.
- (27) Kovács, P., Gerendás, M. (In Press.)
- (28) Frankl, Z. (1956) Lecture at the Congress of Dentists, Budapest.
- (29) Gergely, R., Csillag, A. (1956) In Press.
- (30) Remete, T., Kiss, I., Székely, O. (1956) *Acta Morph. Acad. Sci. Hung. Suppl.* VII, 26.
- (31) Remete, T., Kiss, I., Székely, O. (1955) *Katonaorv. Szemle* 7, 808.
- (32) Berentey, G., et al. (In Press.)